

Sample Exam Questions:

The test includes multiple choice and structural identification questions. Here are some sample questions for use as practice. The answers are provided at the end of the question set.

Multiple Choice: Read the question. Select the best answer choice from the options provided.

1. Which organic molecule has long hydrocarbon chains and is a major element of cell membranes?
 - a. Polypeptides
 - b. Carbohydrates
 - c. Phospholipids
 - d. Nucleotides
2. Which specialized cell of the skin produces pigment?
 - a. Keratinocyte
 - b. Melanocyte
 - c. Langerhans
 - d. Horny
3. In which structure do sperm mature after they are produced?
 - a. the prostate gland
 - b. the epididymis
 - c. the bulbourethral glands
 - d. the seminal vesicles
4. What hormone is important in milk production and maintaining lactation?
 - a. Estrogen
 - b. Oxytocin
 - c. Prolactin
 - d. Adrenaline
5. Which structure and its secretion are correctly matched?
 - a. prostate – fibrinolysin
 - b. bulbourethral gland – thick, acidic fluid
 - c. epididymis – testosterone
 - d. seminal vesicles – fructose
6. Which layer of the uterus is shed during menstruation?
 - a. Perimetrium
 - b. Myometrium
 - c. Endometrium
 - d. Ectometrium
7. Which of the following is a primary function of the glomerulus?
 - a. Filtration
 - b. Reabsorption
 - c. Secretion
 - d. Transport
8. Trace the flow of blood for a nephron.
 - a. peritubular capillaries, efferent arteriole, glomerulus, afferent arteriole

- b. efferent arteriole, glomerulus, afferent arteriole, peritubular capillaries
 - c. afferent arteriole, glomerulus, efferent arteriole, peritubular capillaries
 - d. afferent arteriole, glomerulus, peritubular capillaries, efferent arteriole
9. Which type of tissue is in the image? (Figure 1)
- a. Compact bone
 - b. Fibrocartilage
 - c. Smooth muscle
 - d. Simple squamous epithelial

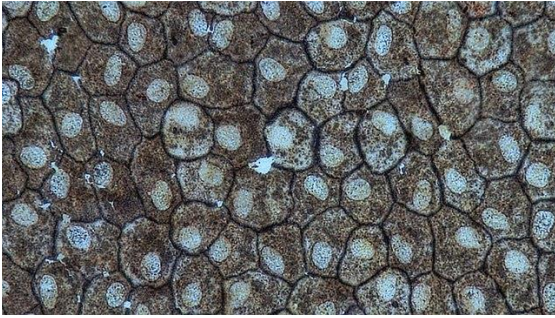


Figure 1

10. Which number in the diagram corresponds to the renal pelvis? (Figure 2)
- a. 3
 - b. 7
 - c. 13
 - d. 14

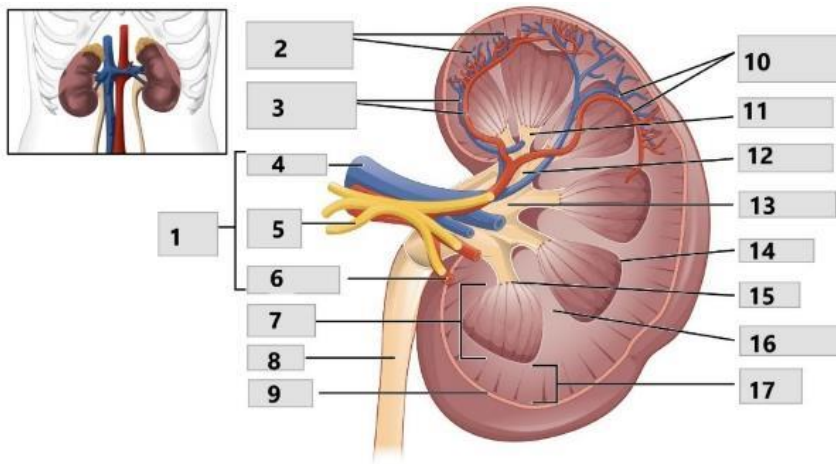


Figure 2

11. Which number represents the medulla oblongata? (Figure 3)
- a. 1
 - b. 2
 - c. 5
 - d. 8

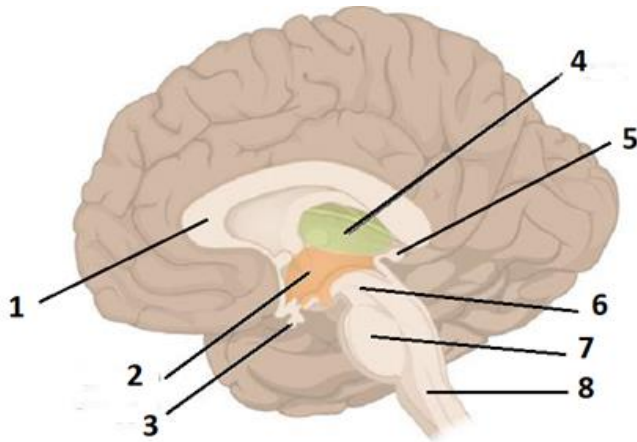


Figure 3

Sample Question Answers:

1. c, 2. b, 3. b, 4. c, 5. d, 6. c, 7. a, 8. c, 9. d, 10. c, 11. d

Image Citation:

Figure 1: "Epithelial Tissues Simple Squamous Epithelium (41722161301)." Berkshire Community College Bioscience Image Library, via Wikimedia Commons.

[https://commons.wikimedia.org/wiki/File:Epithelial_Tissues_Simple_Squamous_Epithelium_\(41722161301\).jpg](https://commons.wikimedia.org/wiki/File:Epithelial_Tissues_Simple_Squamous_Epithelium_(41722161301).jpg). Accessed 8 Apr. 2021. CC0.

Figure 2: "Figure 25.8 Left Kidney," *Anatomy & Physiology*, OpenStax, https://openstax.org/books/anatomy-and-physiology/pages/25-3-gross-anatomy-of-the-kidney#fig-ch26_03_02. Accessed 17 Mar. 2021. CC BY.

Figure 3: "Figure 13.11 The Diencephalon," *Anatomy & Physiology*, OpenStax, <https://openstax.org/books/anatomy-and-physiology/pages/13-2-the-central-nervous-system> Accessed 17 Mar. 2021.